




TONBRIDGE
MEDICAL

Case Report

Stent-assisted coil embolization of right posterior communicating artery aneurysm



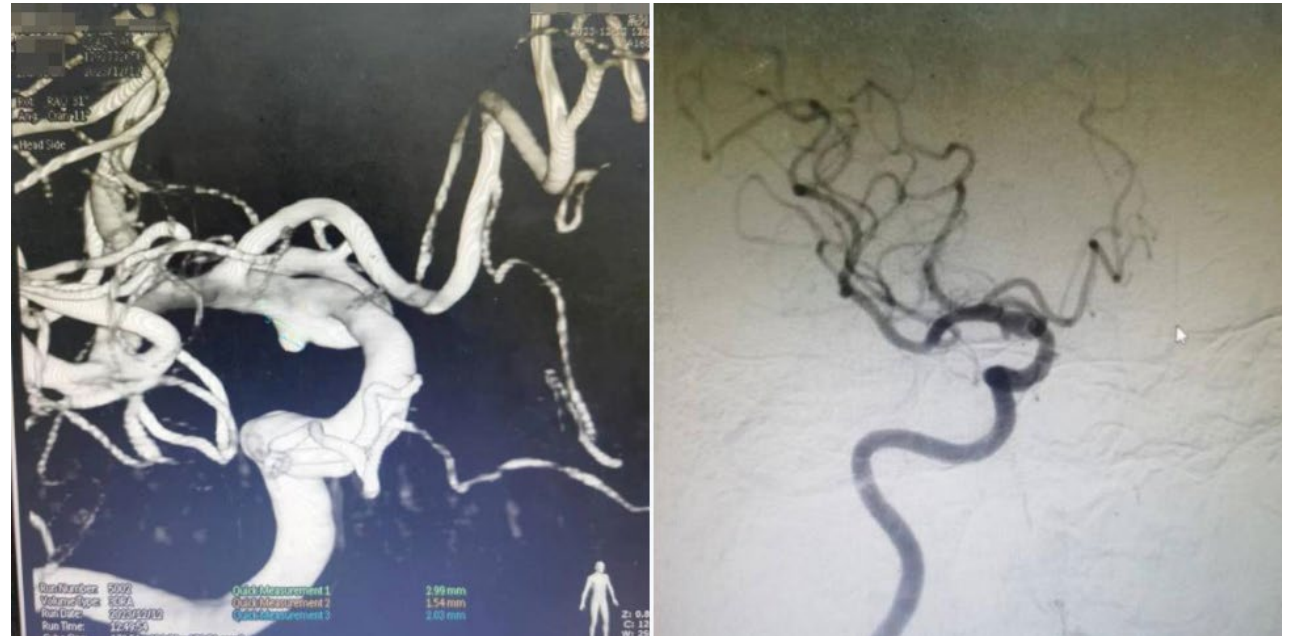Patient information

- Male, 54 years old
- Right posterior communicating artery aneurysm
- GCS score: 8 points
- NIHSS score: 21 points
- mRS score: 4 points

*Courtesy of:
Jian Shen, Southeast Guizhou People's Hospital*

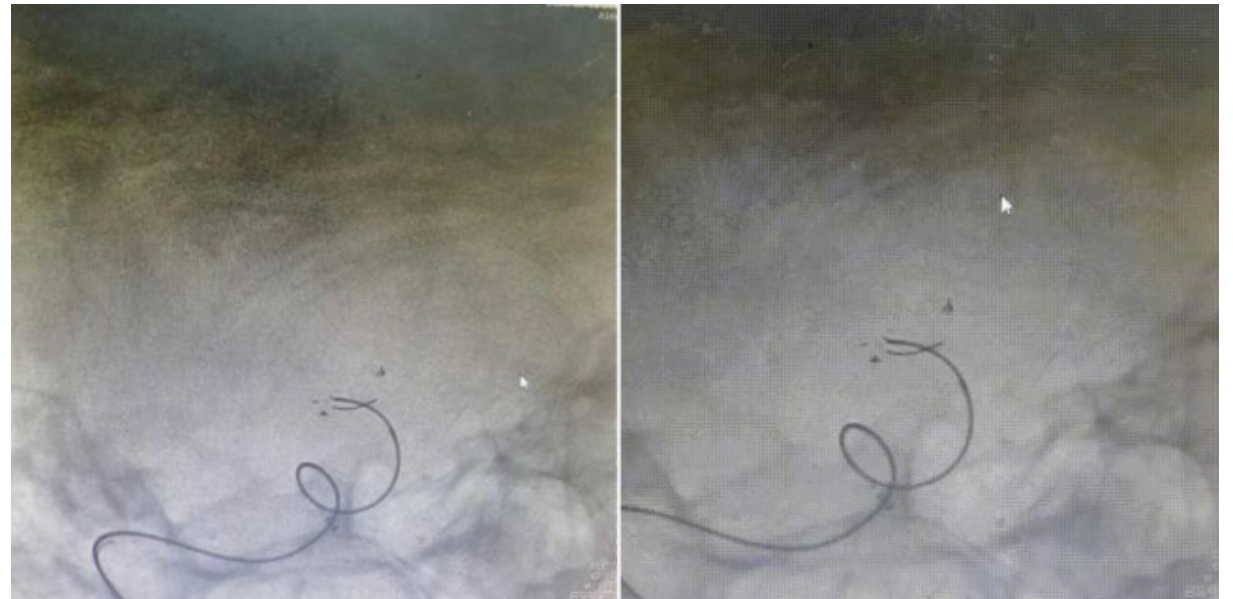Preoperative Examination

- Right PCA aneurysm, size about 2.18mm*1.75mm, neck width 2.03mm
- Left common carotid, external carotid and ICA have good blood flow
- Left vertebral artery, basilar artery and bilateral PCA are patent



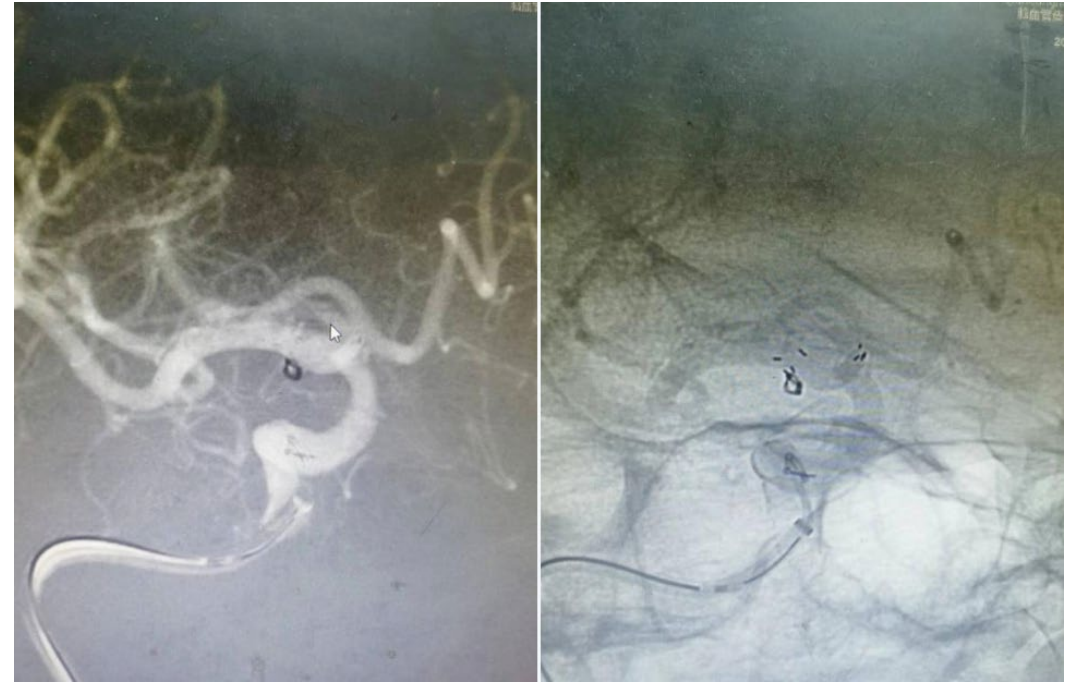
Procedure

- 0.014" guidewire combined with microcatheter to guide the **6F 115cm Cylone Aspiration Catheter** to the C3 segment of the right ICA for enhanced support
- 0.014" guidewire combined with stent microcatheter into the right MCA, and the stent was advanced along the microcatheter



Procedure

- Filling the first frame coil along the microcatheter, **GEKKO Coil 2mm*4cm** was successfully detached
- Filling in the second **GEKKO coil 1mm*2cm**
- Continue to fill the finishing coil: **GEKKO Coil 1mm*2cm** for finishing



Postoperative Angiography

- Angiography showed no residual of the aneurysm, good shape, and open posterior communication artery

