




TONBRIDGE
MEDICAL

Case Report

Treatment of Bilateral C7 Segment Mirror
Aneurysms



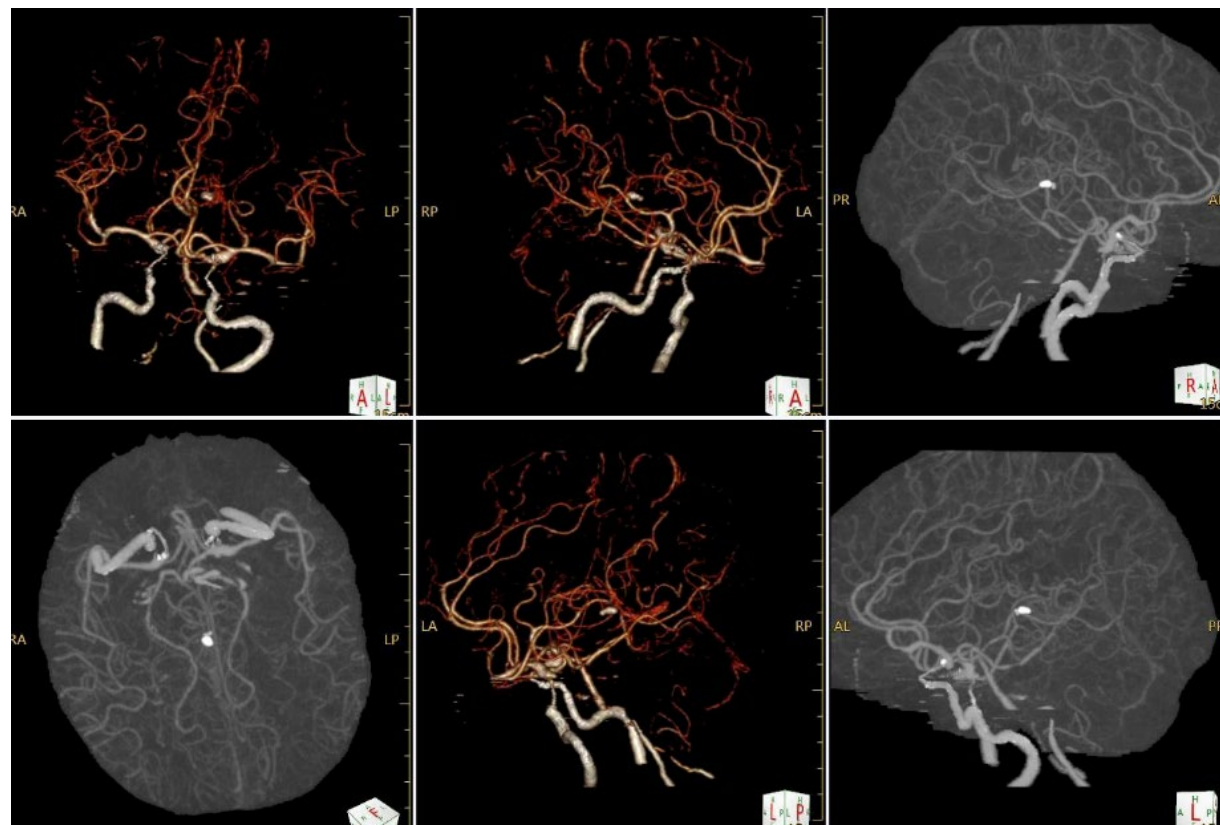
Patient information

- Male, 53 years old.
- The patient was confused and unable to speak, and a subarachnoid hemorrhage was seen on CT
- GCS score: 8 points
- NIHSS score: 22 points
- mRS score: 5 points
- Hunt-Hess grading: Grade III

*Courtesy of:
Dongpeng Qiu, Guangdong Second People's Hospital*

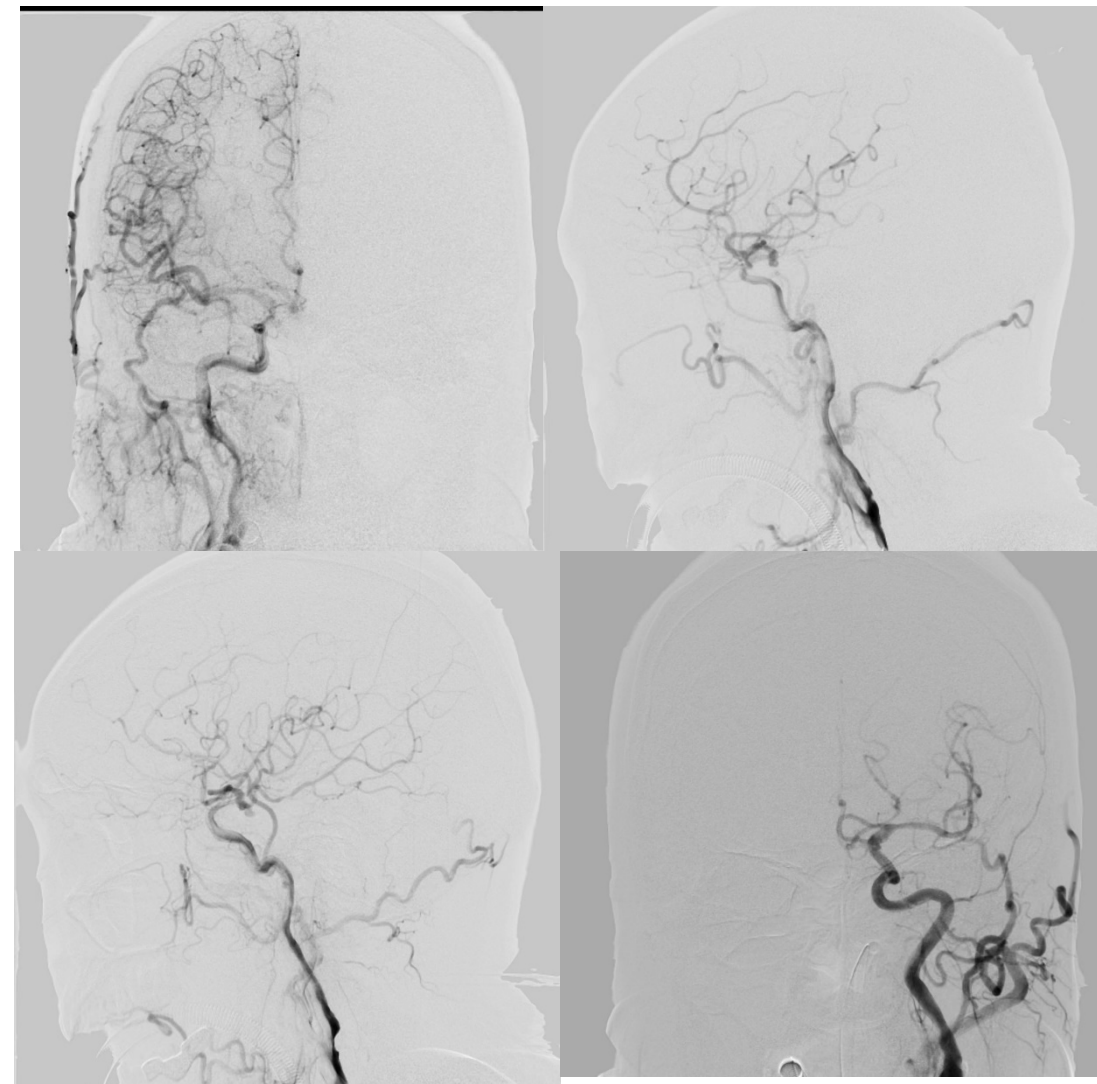
Preoperative Examination

- Bilateral ICA segment C7 aneurysms
- Bilateral stenosis of the P2 segment of the PCA
- Left ICA C1 segment stent implanted



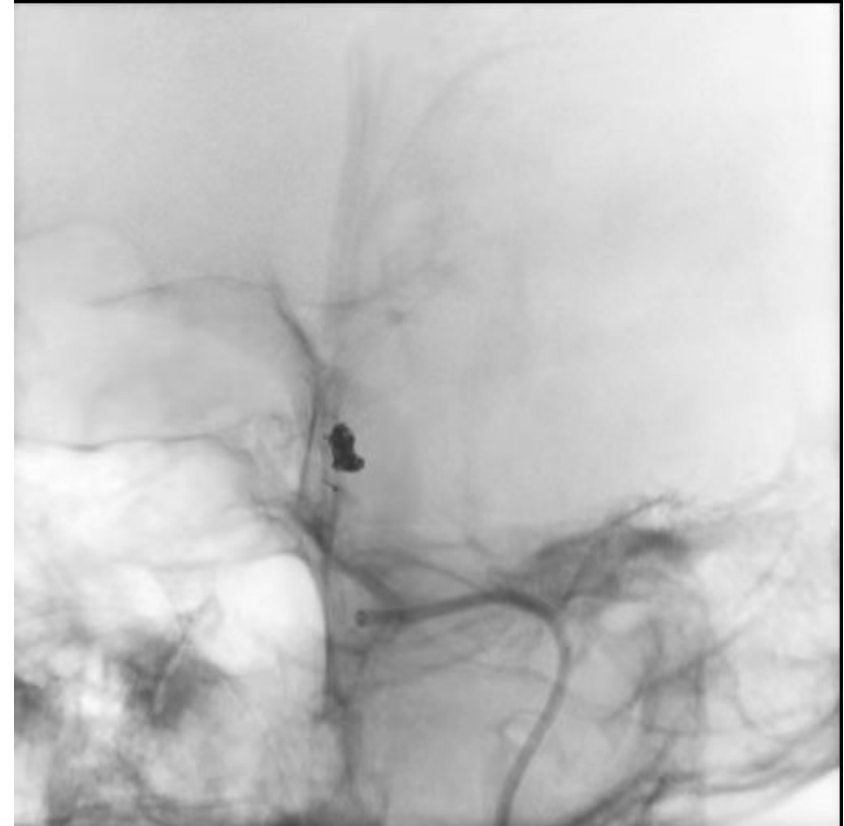Preoperative Examination

- DSA showed a 3mm narrow carotid aneurysm in the C7 segment of the left ICA and a 2mm relatively wide carotid aneurysm in the C7 segment of the right ICA.



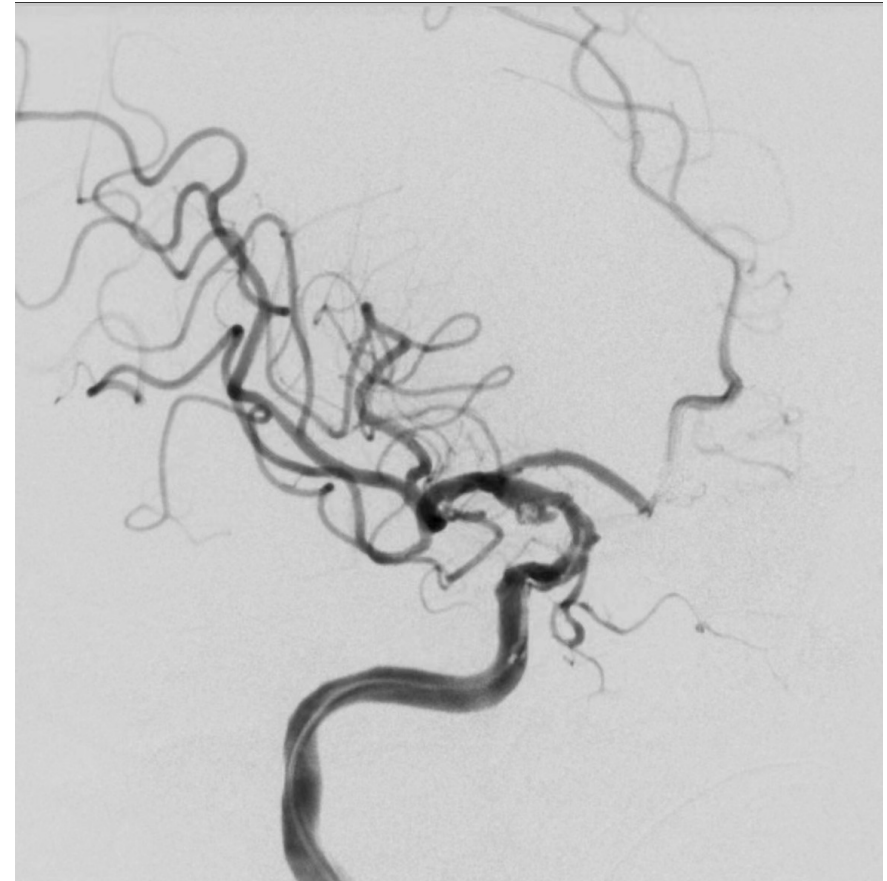
Procedure

- The 6F 115cm Cylone aspiration catheter was introduced to the C4 segment of the left carotid artery for reinforced support.
- The first GEKKO coil 3.5mm*6cm was filled along the microcatheter and formed into a basket, and was followed by the filling of GEKKO coils 3mm*8cm, 2.5mm*6cm, 2mm*8cm, and 2mm*6cm.



Procedure

- The 6F 115cm Cylone aspiration catheter was guided to the C1 segment of the right ICA as support.
- GEKKO coils 2.5mm*4cm and 2mm*6cm were used along with the 0.021" microcatheter semi-released Lvis 3.5mm*17mm stent for assisted embolization, and the GEKKO coil 1.5mm*4cm was released as a finish.



Postoperative Angiography

- Angiography showed no residual of the aneurysm, good shape, and open posterior communication artery.

