



TONBRIDGE
MEDICAL

Case Report

Treatment of bilateral ophthalmic aneurysms

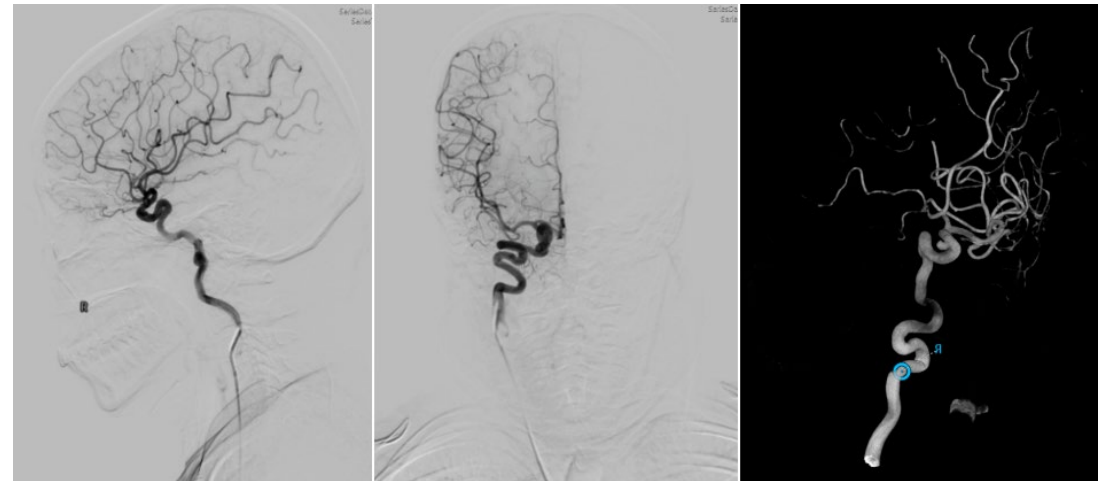
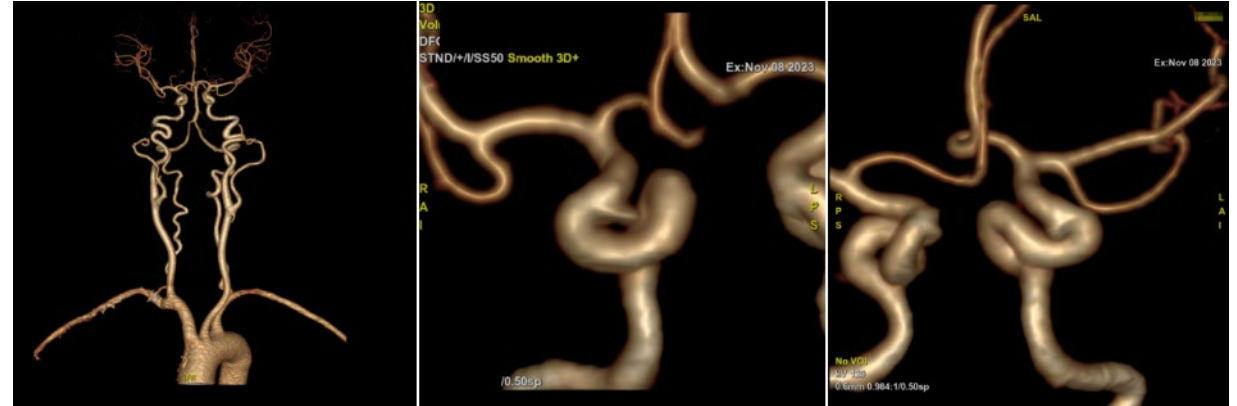


Patient information

- Female, 59 years old.
- Paroxysmal dizziness for 10 years
- Bilateral ophthalmic artery segmental aneurysms were found 1 month ago

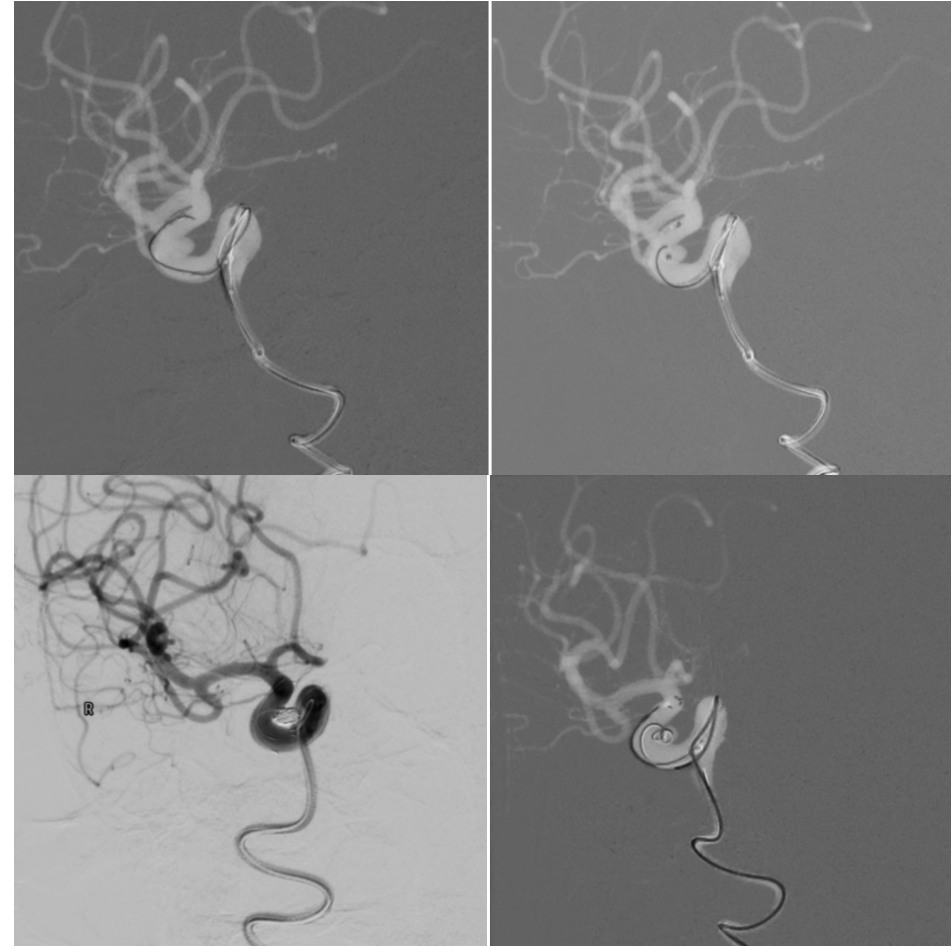
Preoperative Examination

- CTA showed bilateral ophthalmic segment aneurysms of the internal carotid artery
- Preoperative DSA: clear bilateral ophthalmic artery segmental aneurysms with tortuous internal carotid arteries



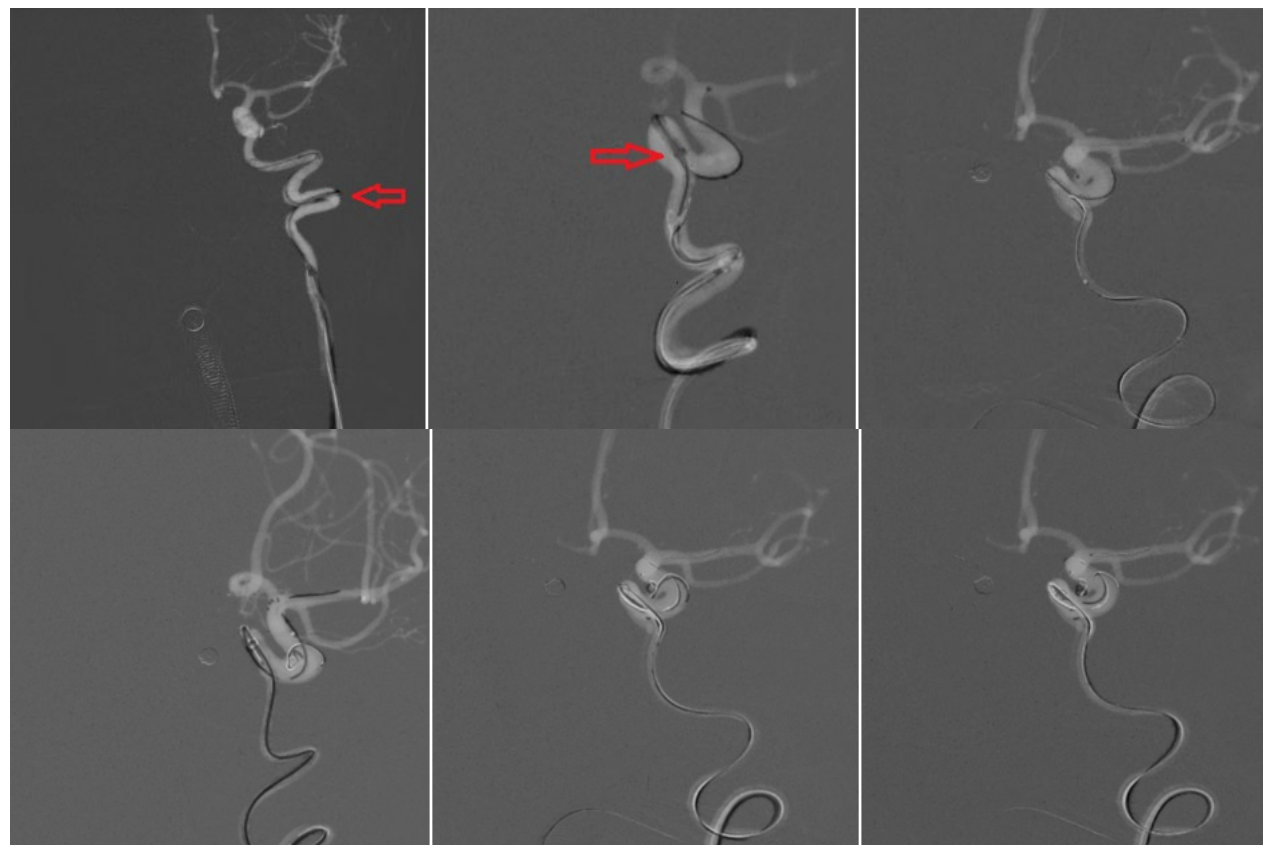
Procedure

- Stent-assisted coil embolization of bilateral ophthalmic segment aneurysms
- Cylone™ Aspiration Catheter was guided by 0.017" microcatheter and 0.021" stent microcatheter
- The stent was released directly in situ, and the stent just covered the aneurysm neck



Procedure

- Treatment of left aneurysm: Cylone™ Aspiration Catheter was guided by 0.017" microcatheter and 0.021" stent microcatheter



Postoperative Angiography

- Postoperative angiography from multiple angles showed that the aneurysm were completely embolized

