



TONBRIDGE  
MEDICAL

# Case Report

Thrombectomy for middle cerebral artery  
fenestration malformation



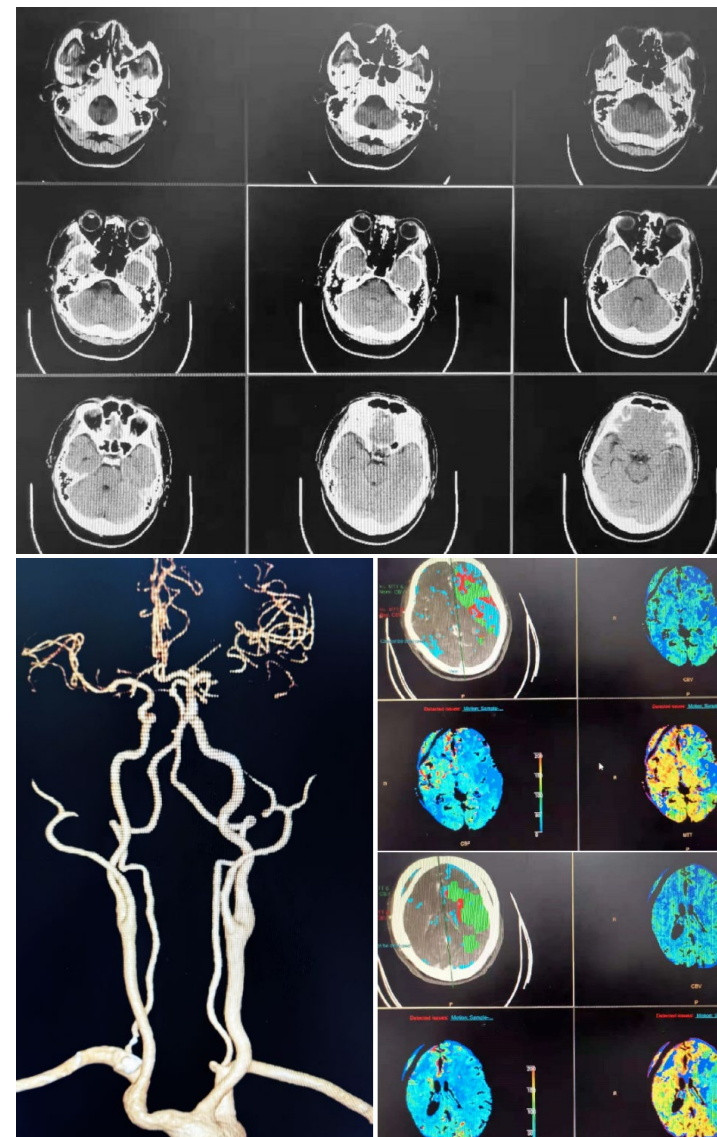
## Patient information

- Male, 47 years old
- Weakness of the right limb with aphasia for 2 hours
- Cerebral infarction (slurred speech 1 month ago, improved after treatment), hypertension
- NIHSS:18 scores

*Courtesy of:  
Lei Zhang, The First Affiliated Hospital of Naval Military Medical  
University*

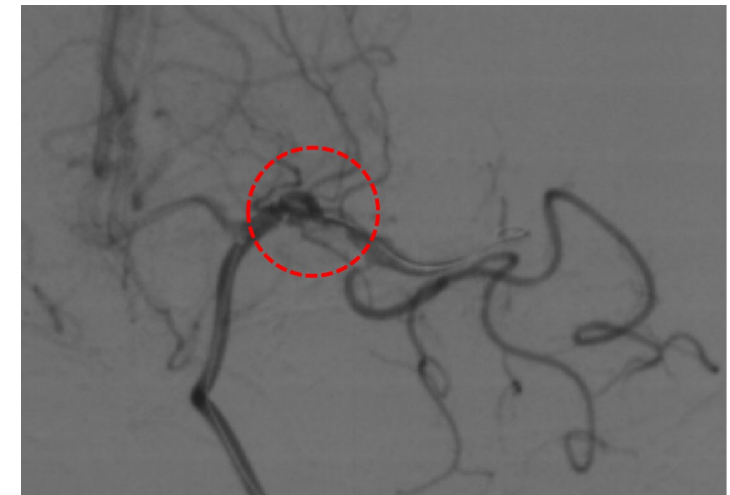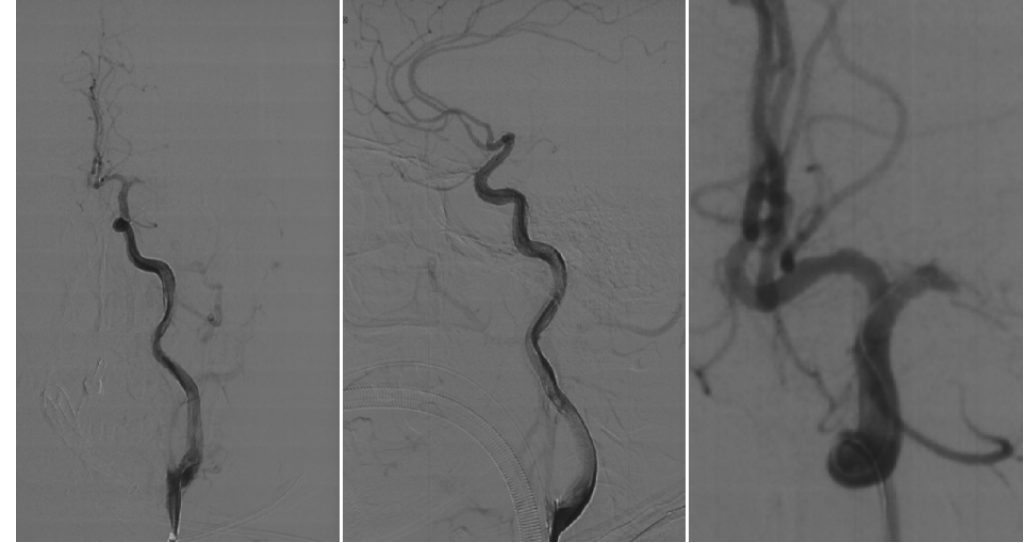
## Preoperative Examination

- Acute cerebral infarction
- Occlusion of the M1 segment of the left middle cerebral artery



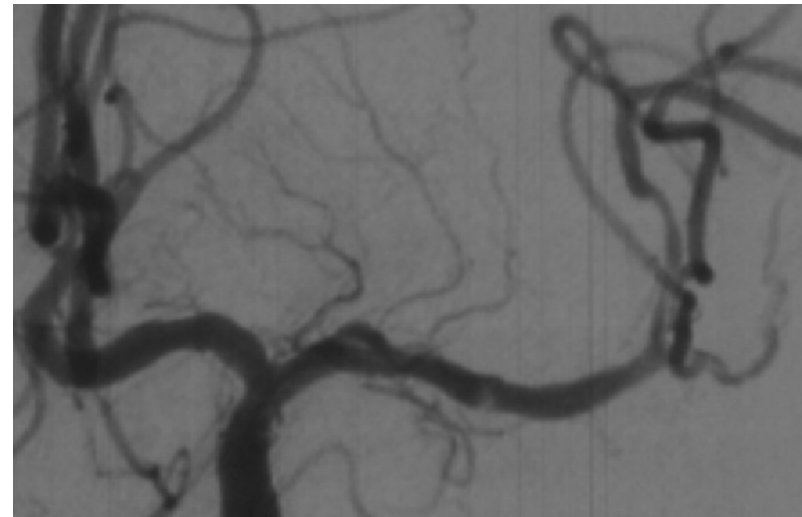
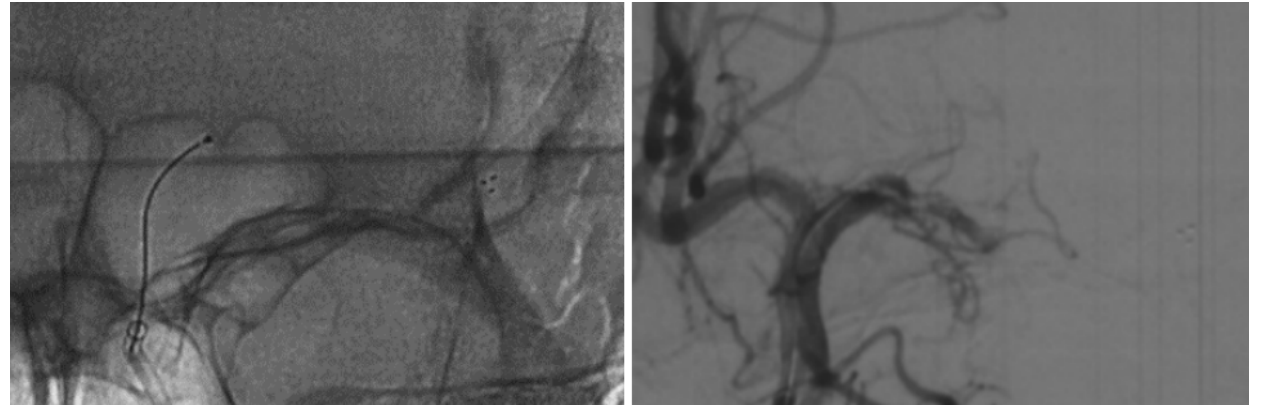
## Procedure

- Angiography showed occlusion of the left middle cerebral artery with a residue that did not resemble a common embolic lesion
- No obvious atherosclerotic plaque was found in the other vessels, and stent thrombectomy was performed



## Procedure

- At the first thrombectomy, the beginning of M1 segment showed a double track sign, which suggested the possibility of fenestrated malformation
- The vessel was recanalized after the second thrombectomy
- A 6F 125cm Cylone intracranial aspiration catheter was used throughout the procedure



## Postoperative Angiography

- Anteroposterior and lateral angiography showed recanalization at eTICI 3

